

Diseases of meagre, greater amberjack and wreckfish not described in DoW

Dr. Pantelis Katharios

Maria Smyrli, Panos Kalatzis, Marianna Tsertou

Institute of Marine Biology, Biotechnology and Aquaculture

Hellenic Centre for Marine Research

Annual Coordination Meeting, Nancy 2016



Meagre: case 1

Meagre.... Somewhere in Greece

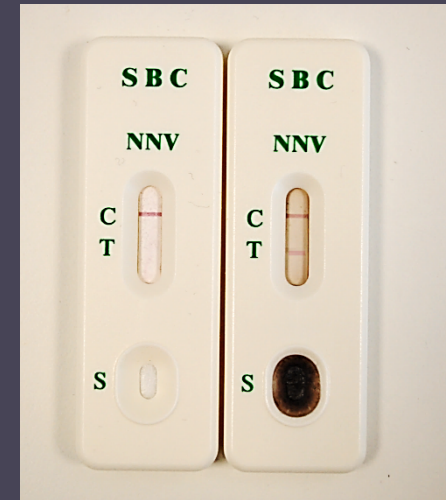

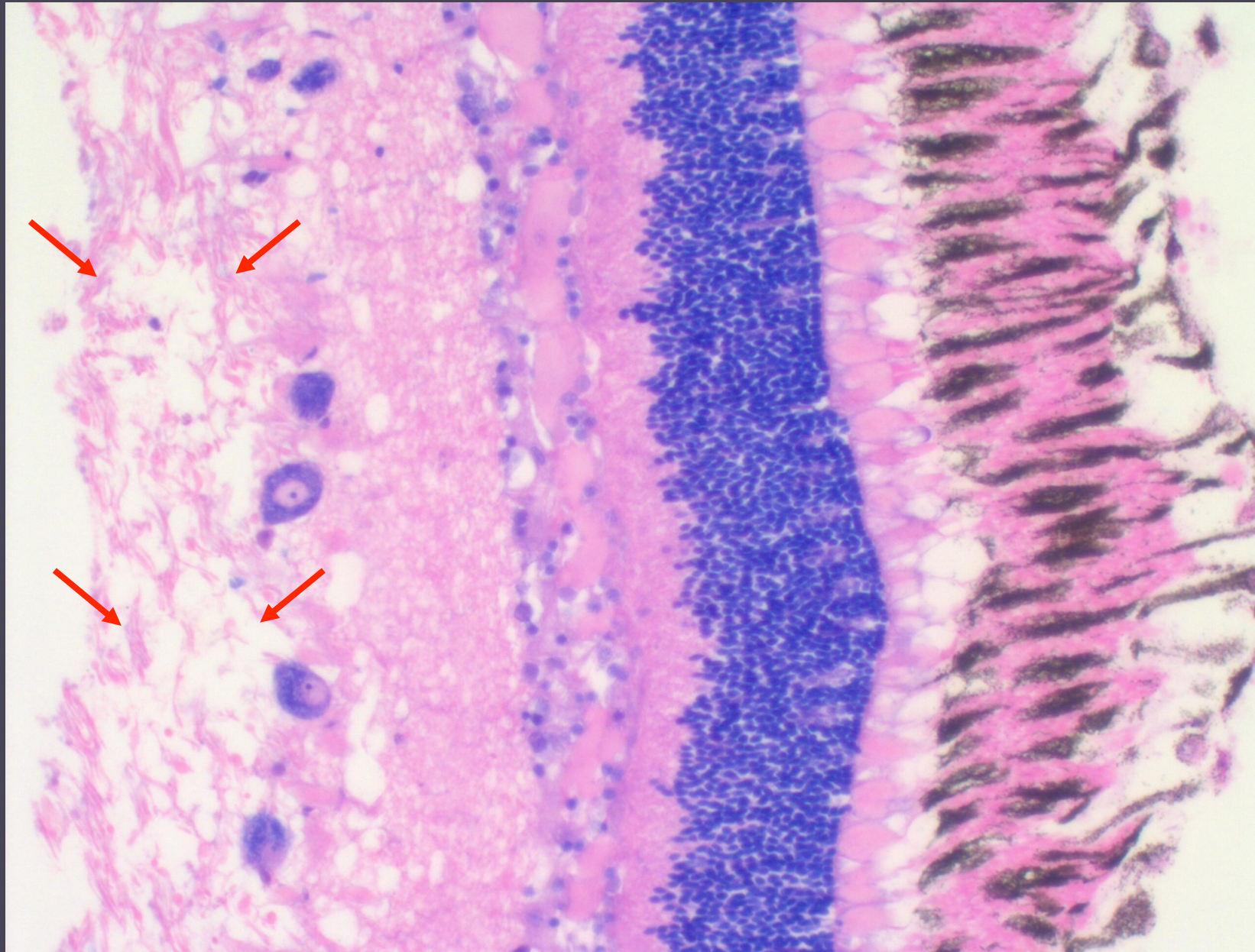
Clinical picture

- Maximum Mortality ~ 2-5% daily
- Onset with temperature rise
- No external lesions
- Abnormal behavior (swirling at the surface with belly up)

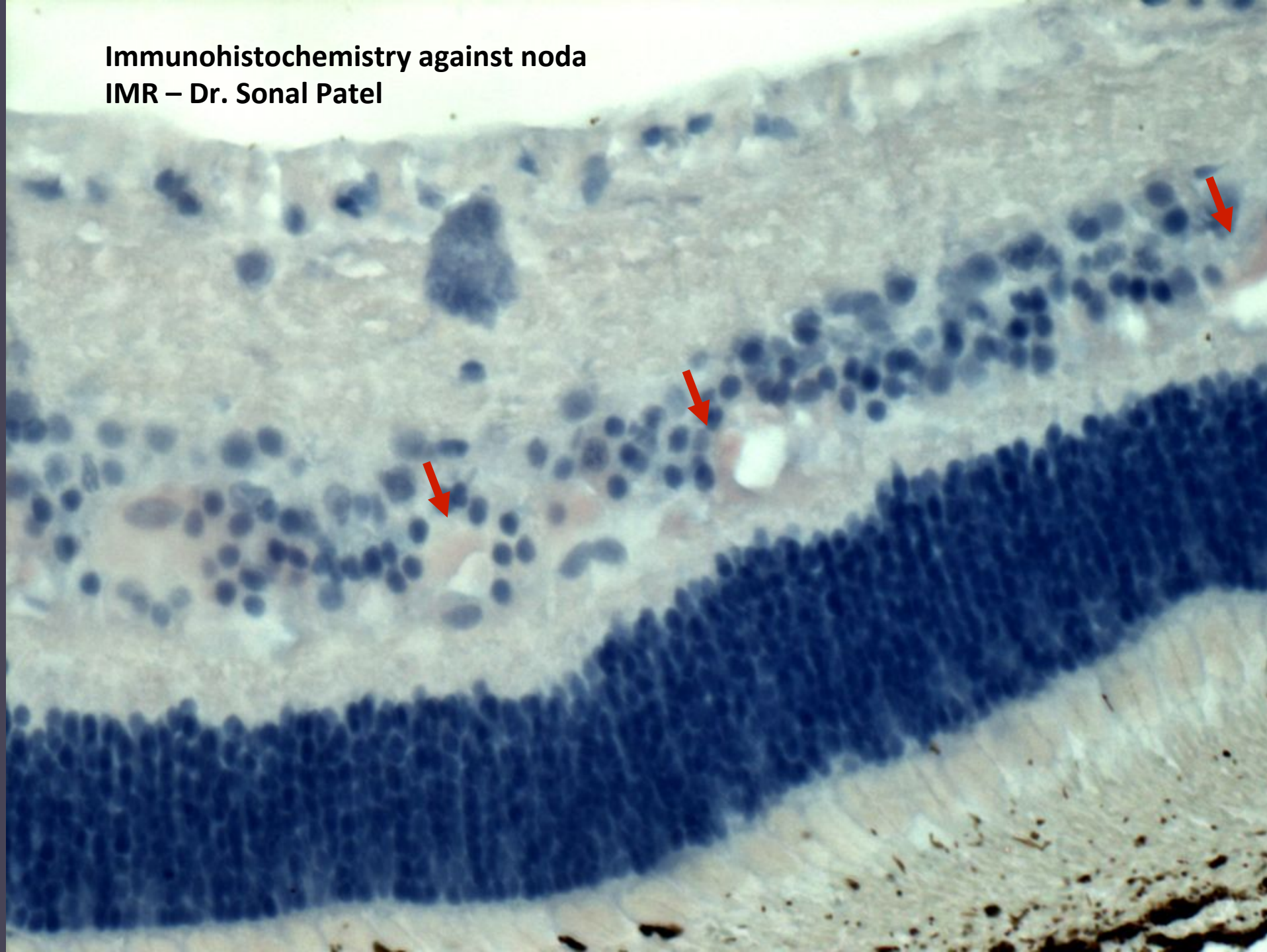
Lab results

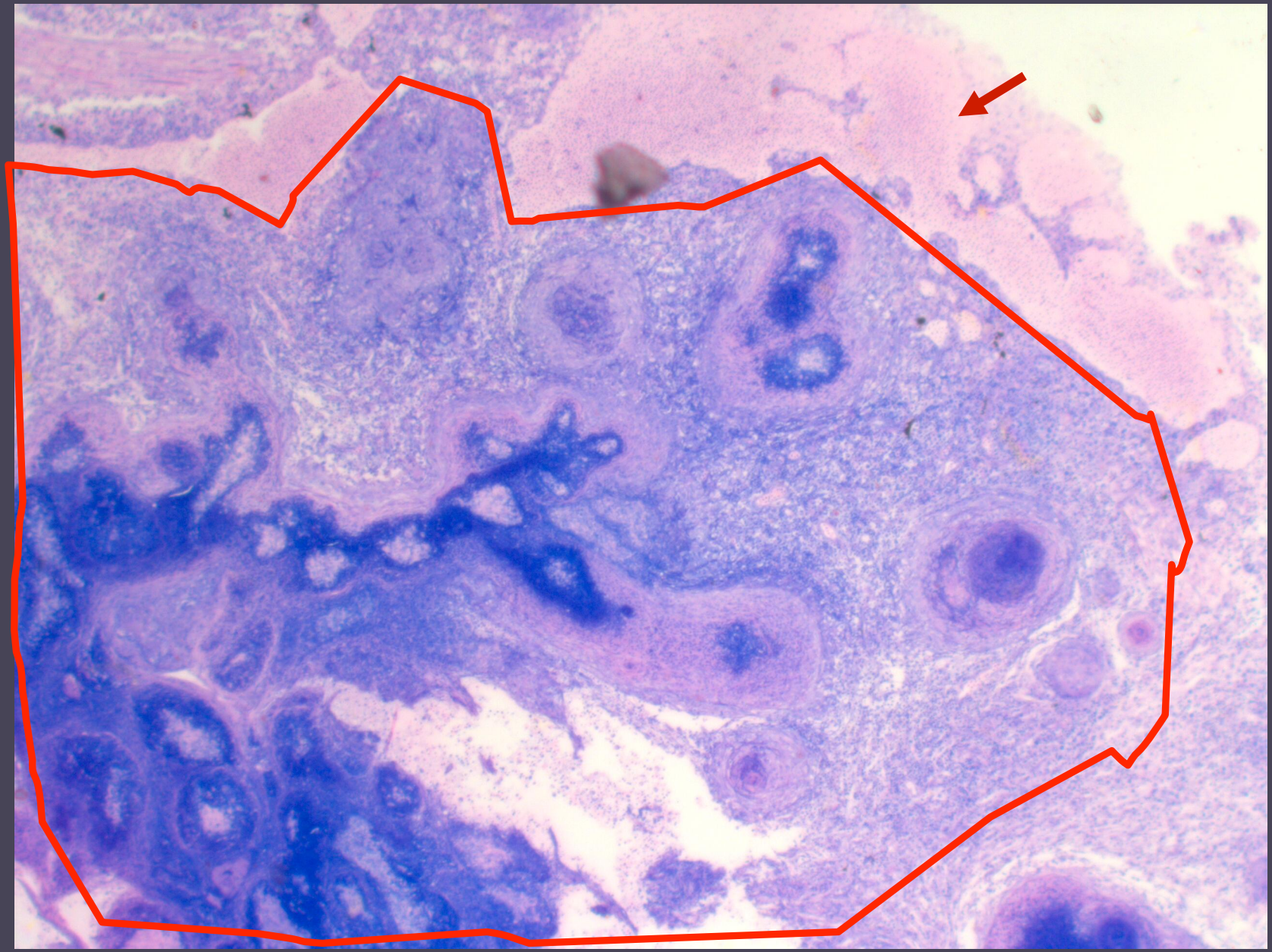
- Rapid test for noda: positive
- PCR for noda: positive
- Samples sent to IMR (Sonal Patel)
- qPCR: IMR (Sonal)
- Immunohistochemistry: IMR (Sonal)
- Bacteriology: isolation of *Photobacterium damsela* subsp. *piscicida* (Dr. Panos Varvarigos- fishvet)
- Histology (HCMR)

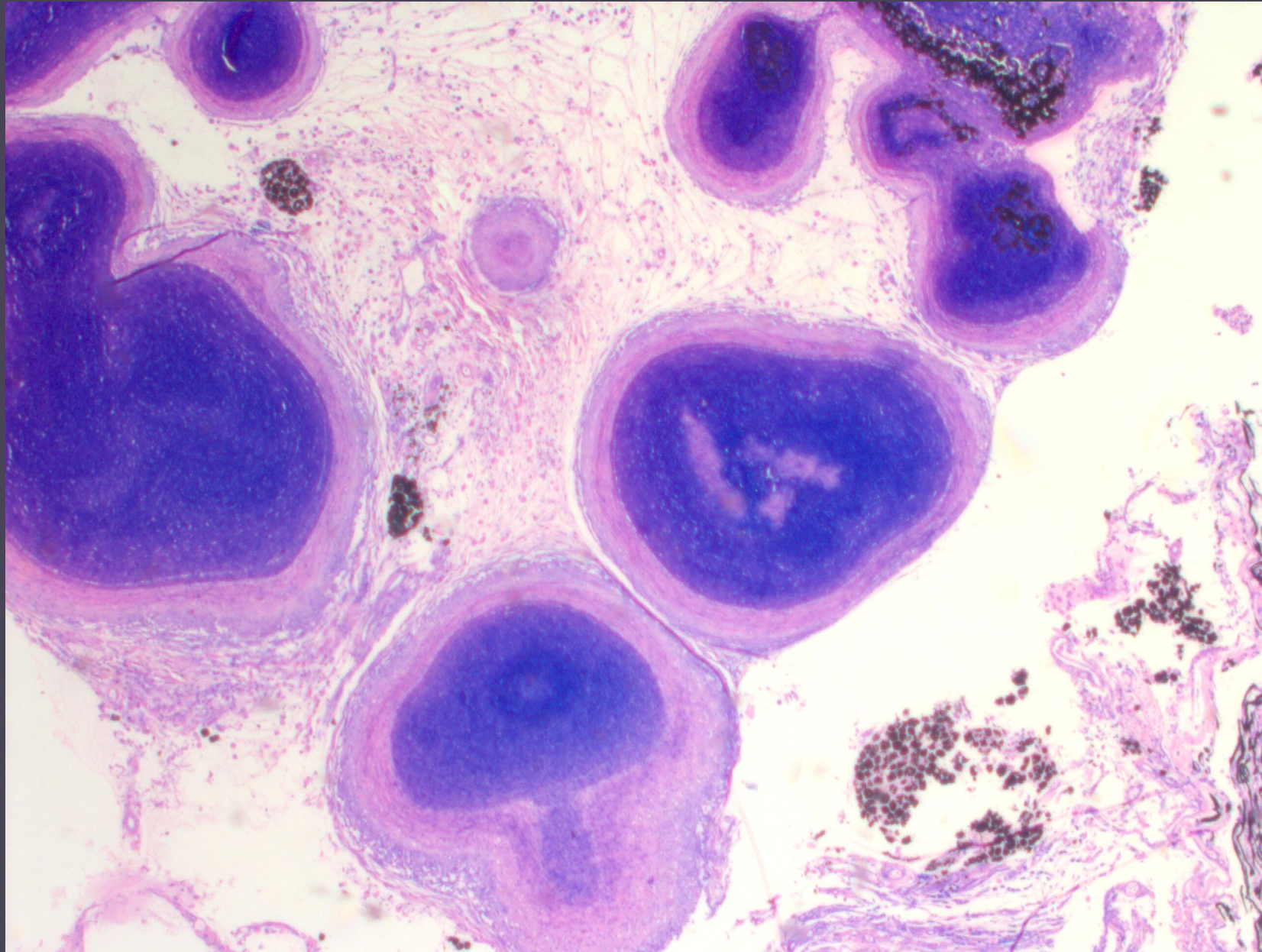




Immunohistochemistry against noda
IMR – Dr. Sonal Patel







In conclusion

A case where meagre:

1. Are carriers of Nodavirus and some present symptoms of the disease
2. Have extensive granulomatosis affecting nervous system
3. Have pasteurella

Hard to say which is the main problem

First case of noda in cultured meagre showing signs of the disease

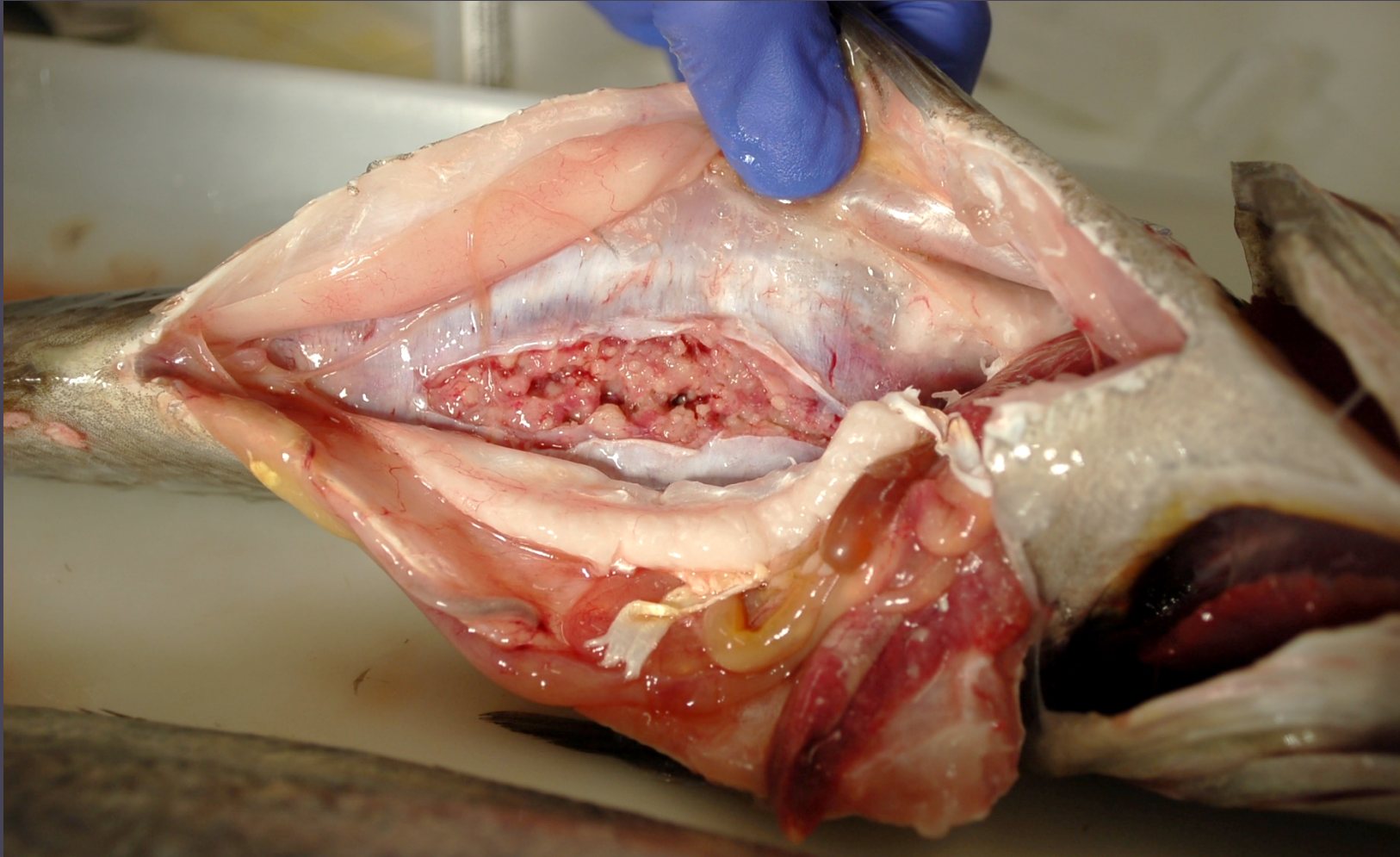
Difficult to publish !

Meagre: Case 2

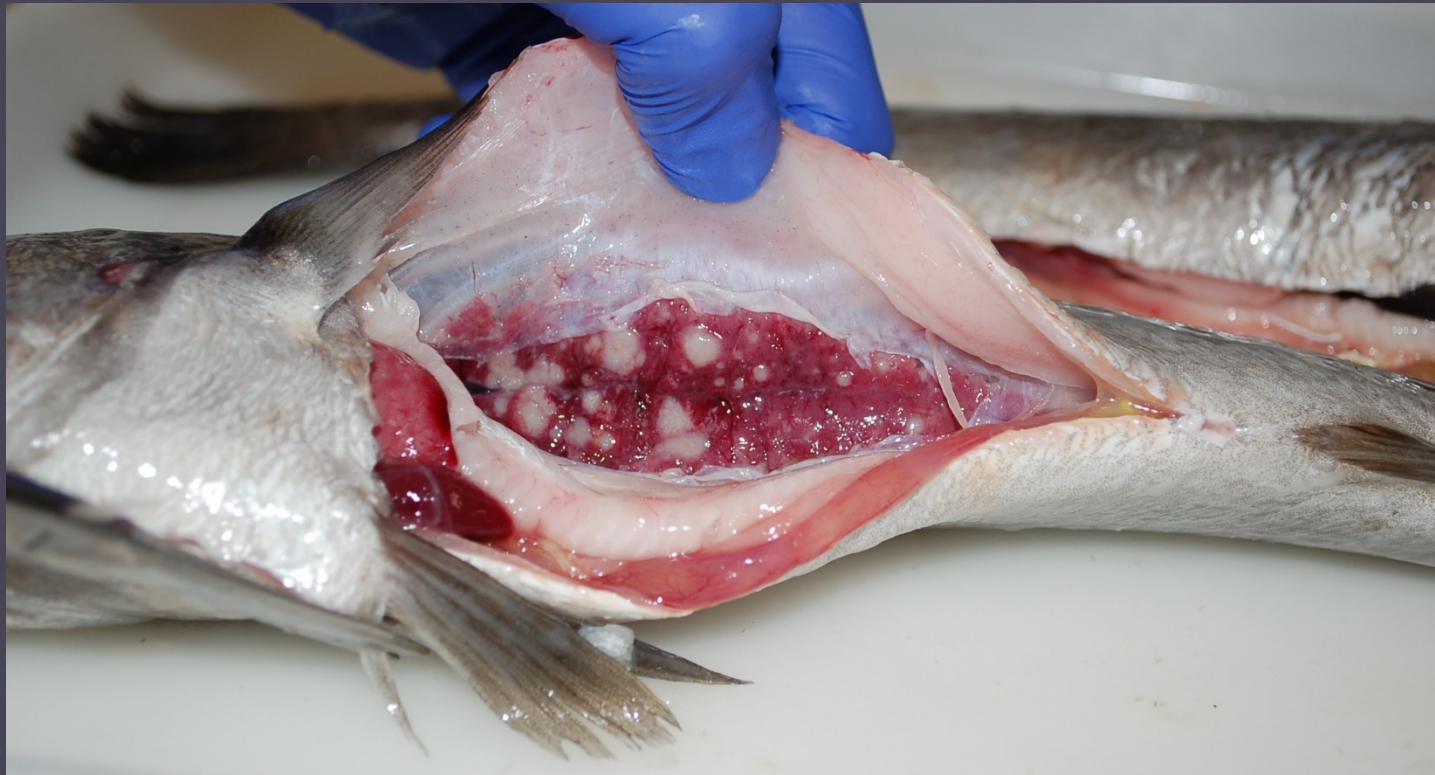....somewhere else in Greece



Internally...

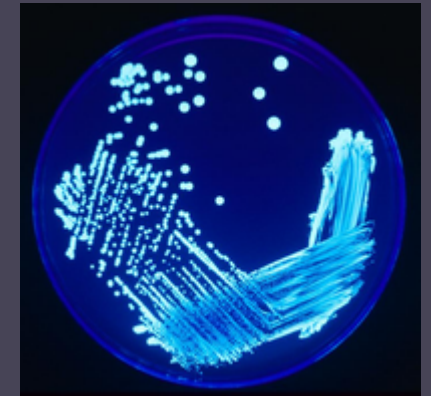


However some lesions looked differently



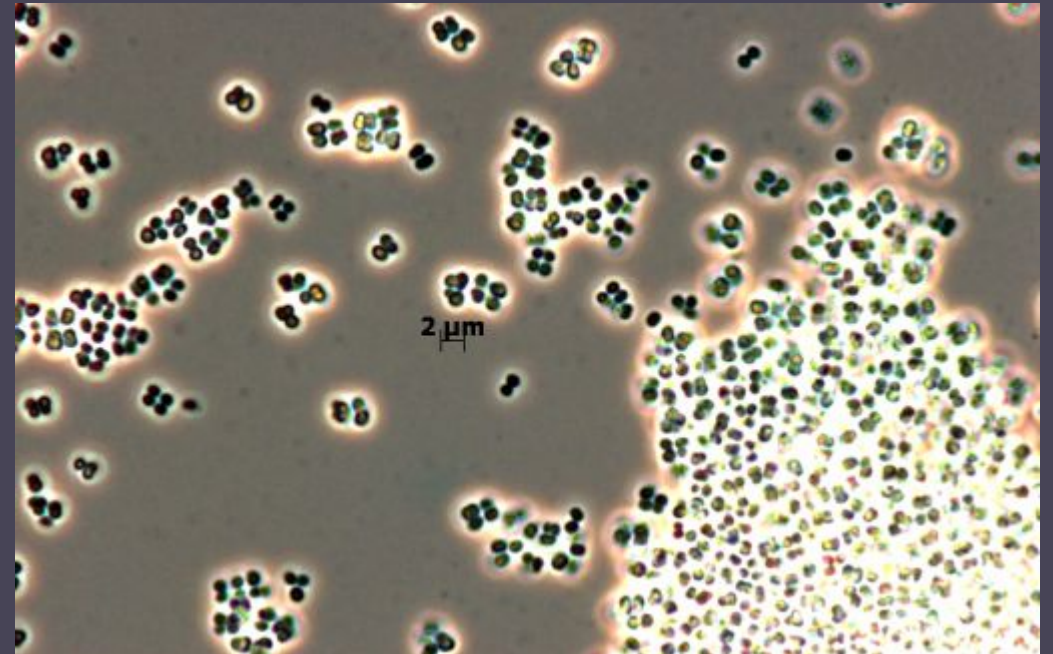
Sampling

- Bacteriology (TSA, BHIA, Lowenstein-Jensen)
- Histology (polychrome stain, Ziehl-Neelsen)
- PCR against *Nocardia* spp., *Mycobacterium* spp. and *Mycobacterium marinum*




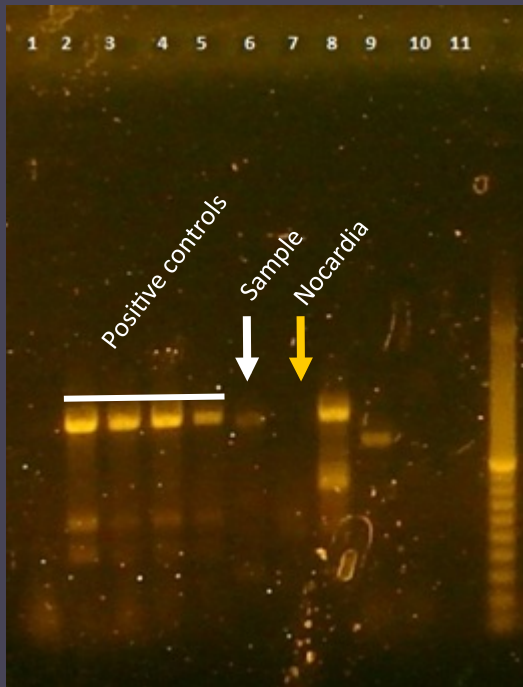
Bacteriology

- TSA: *Micrococcus lylae* + some other strains currently under analysis
- Lowenstein-Jensen: mixed culture
- Reculture from L-J: failed

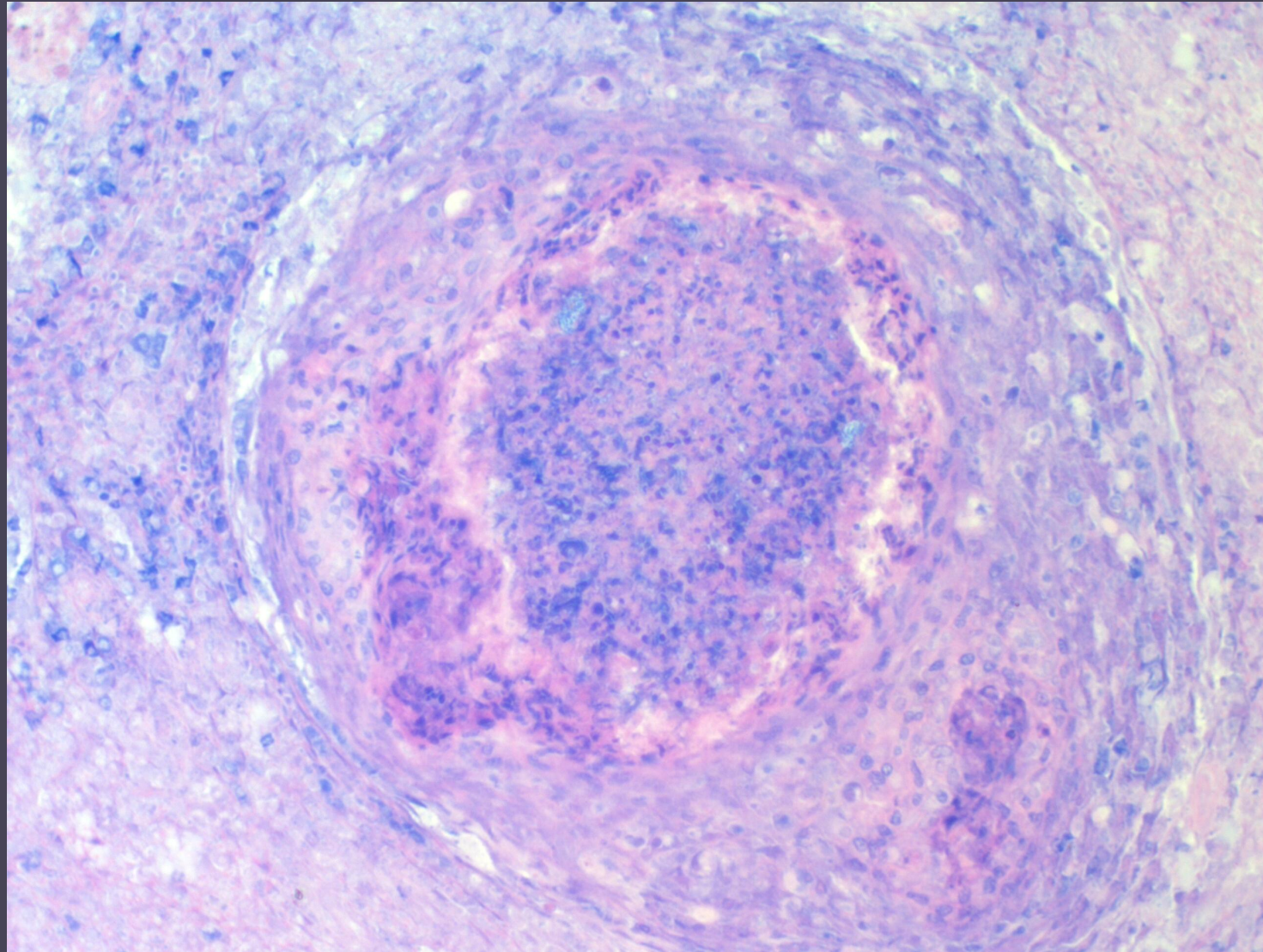


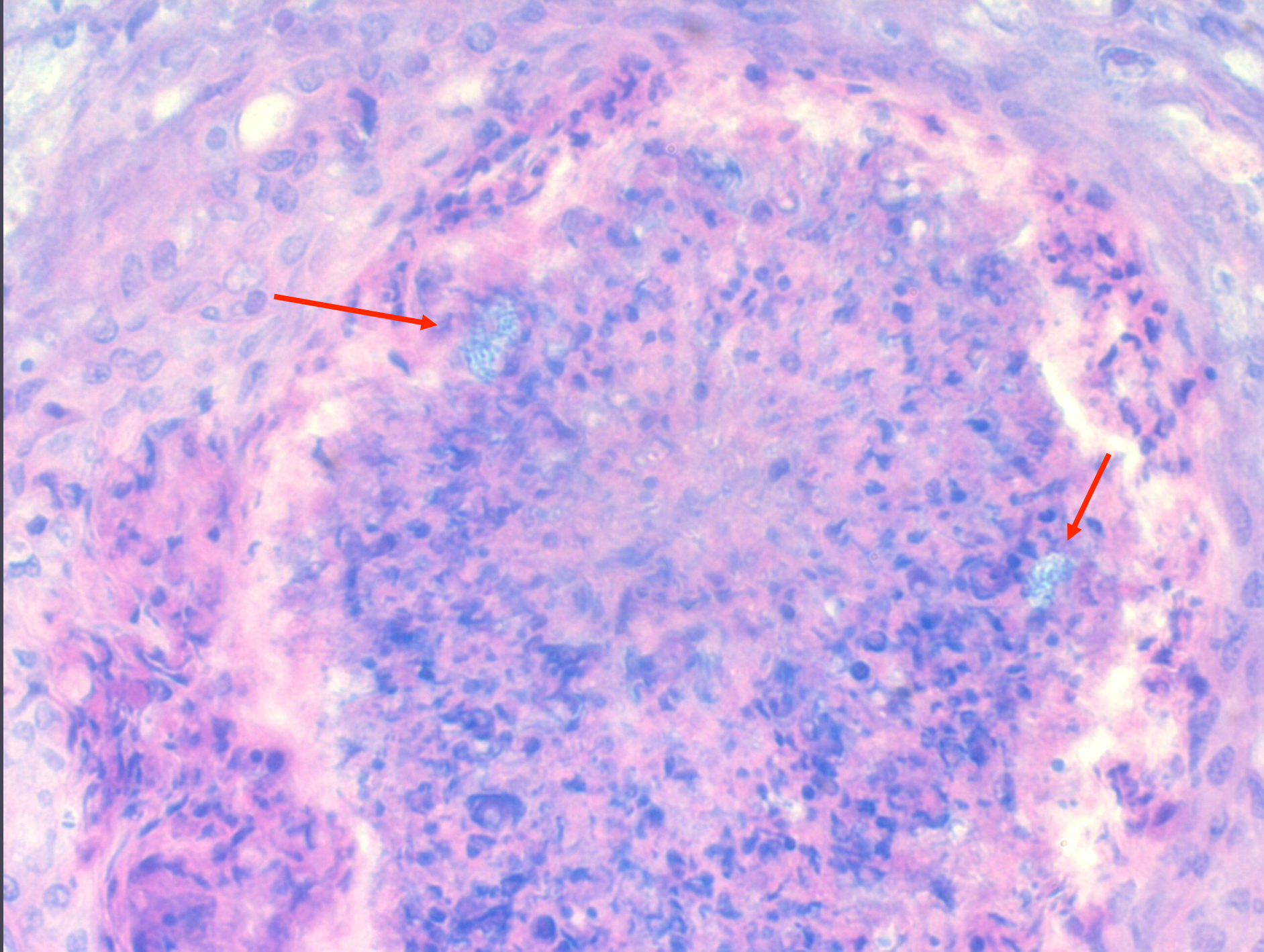
PCR

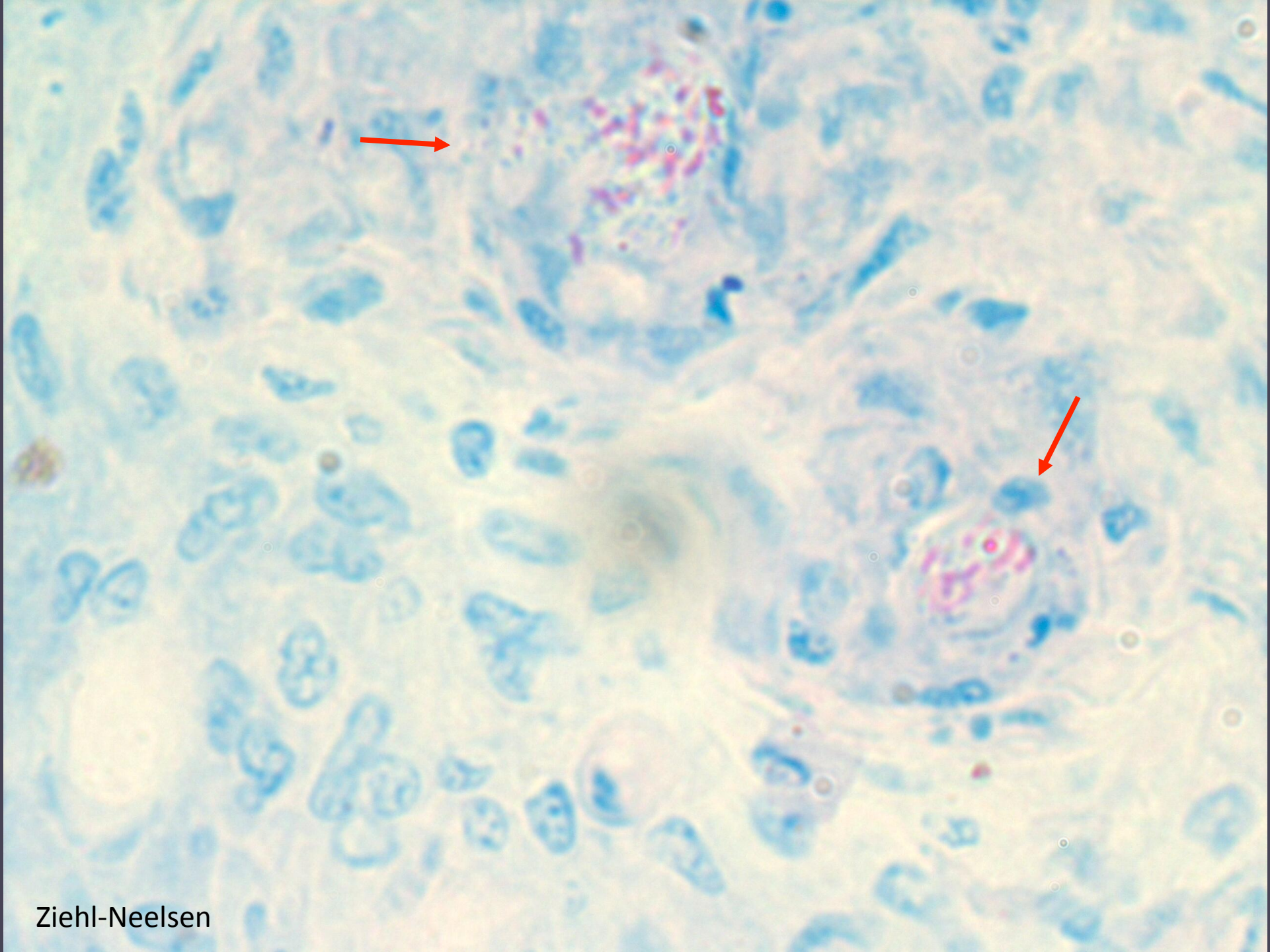
- Genome extraction from L-J medium
- PCR for Nocardia and Mycobacterium
- *Mycobacterium marinum*



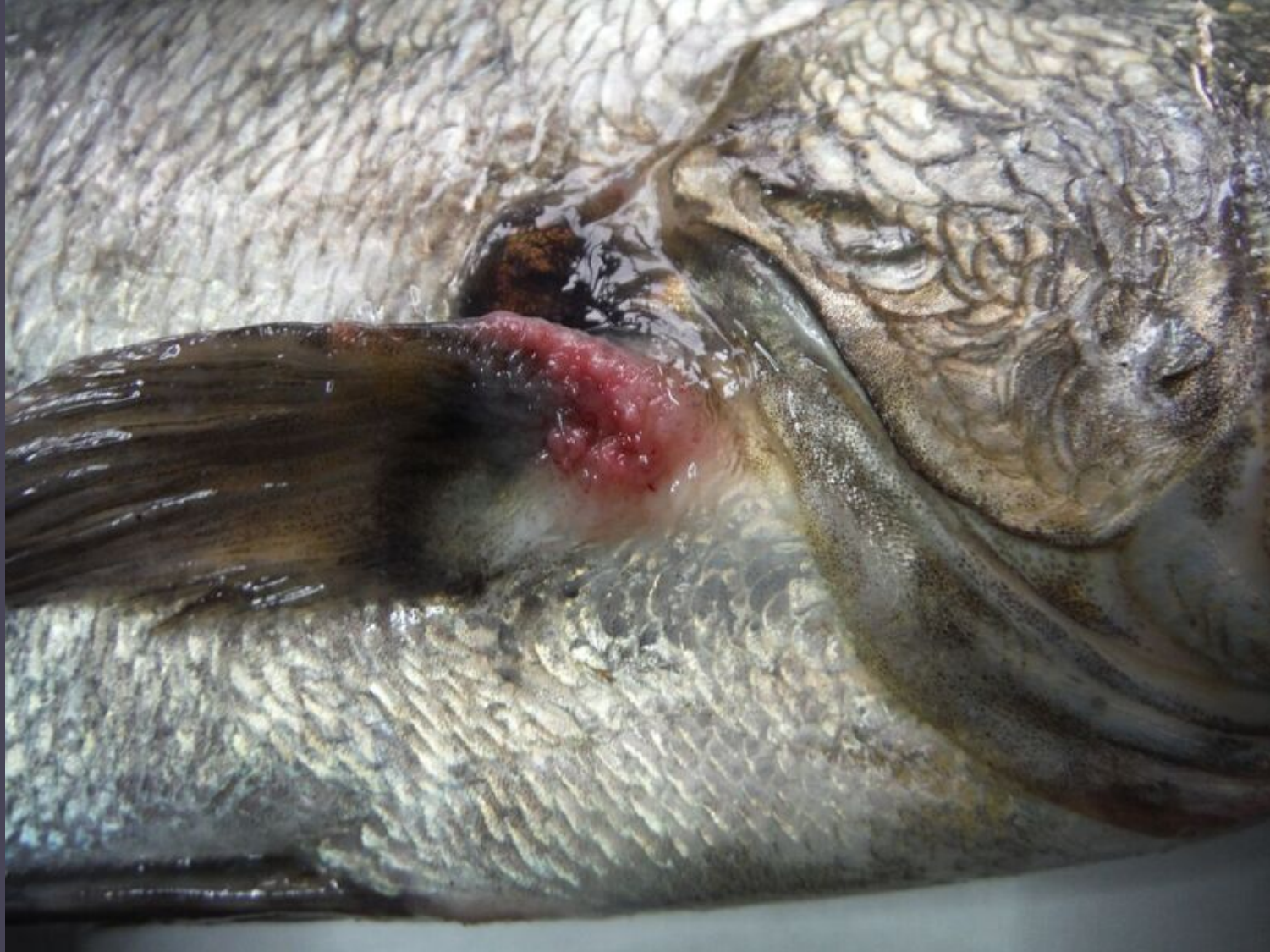Histology







Meagre from Spain

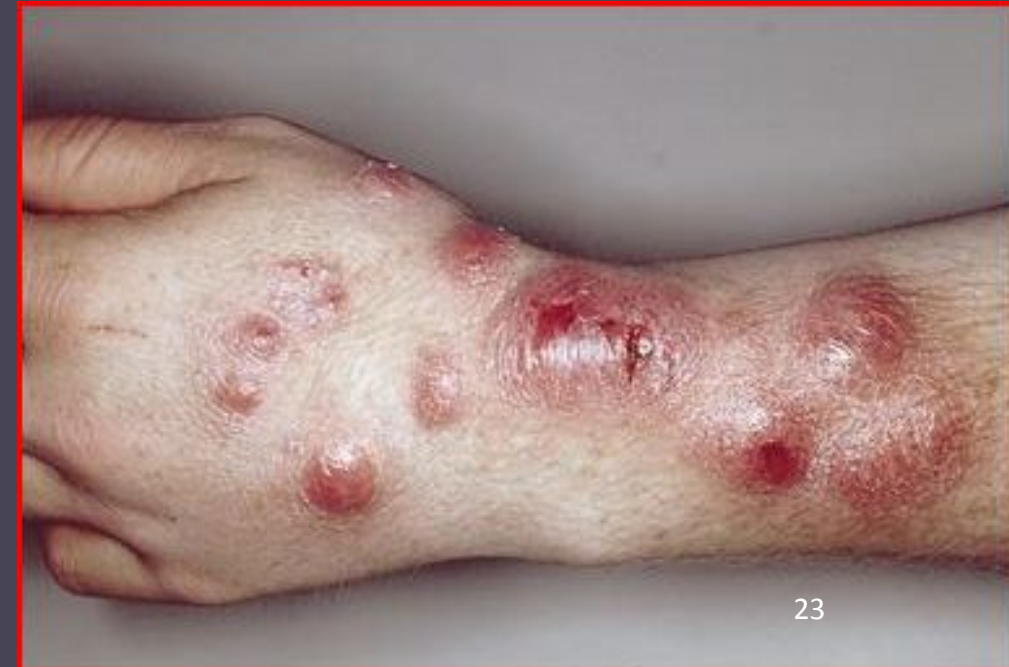



Conclusions

- Infection by *Mycobacterium marinum*
- Co-existence with systemic granulomatosis
- Difficult to distinguish
- Absence of Nocardia
- Serious disease, hard to treat
- Zoonotic
- Recently reported in Turkey

1. Avsever, M.L., Çavuşoğlu, C., Günen, M.Z., Yazıcıoğlu, Ö., Eskiizmirli, S., Didinen, B.I., Tunalıgil, S., Erdal, G., Özden, M., 2014. Bull. Eur. Ass. Fish Pathol 34, 4.
2. Timur, G., Ürkü, Çanak, Erköse Genç, G., Erturan, Z., 2015. Isr. J. Aquac. - Bamidgeh 67, 1–8.



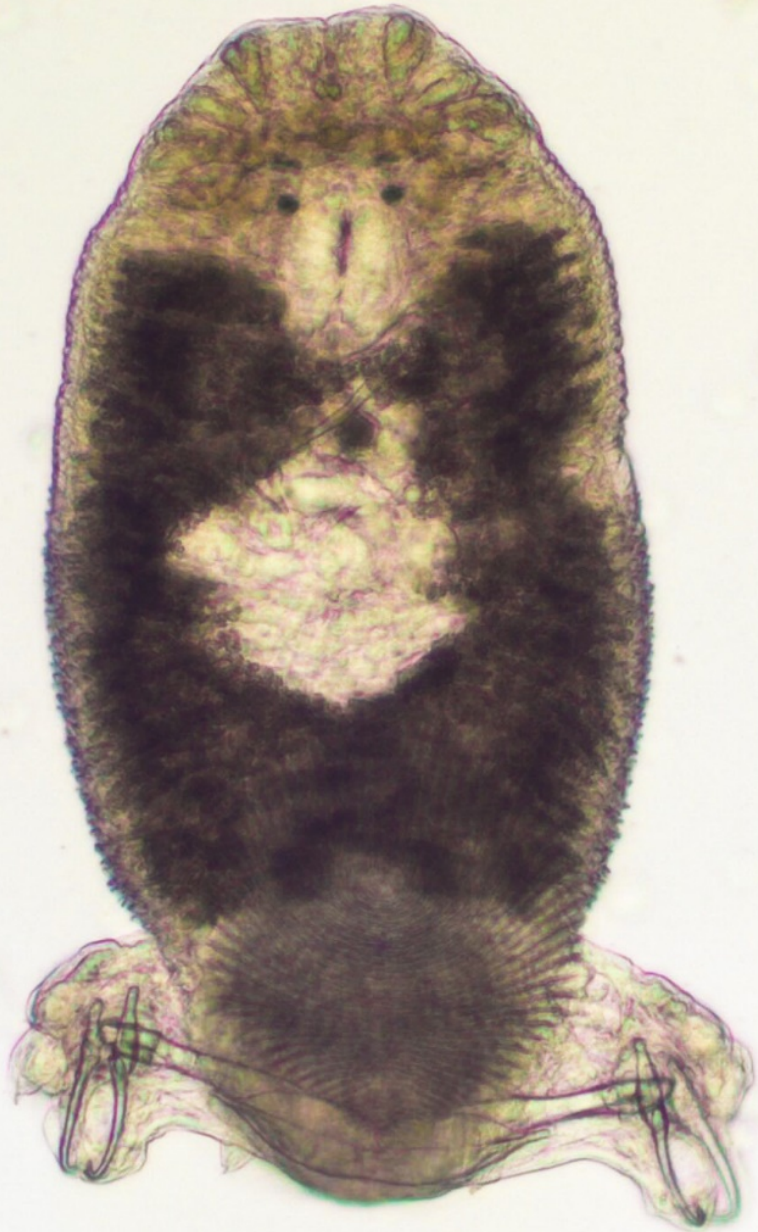Meagre: Case 3

Meagre broodfish with monogeneans

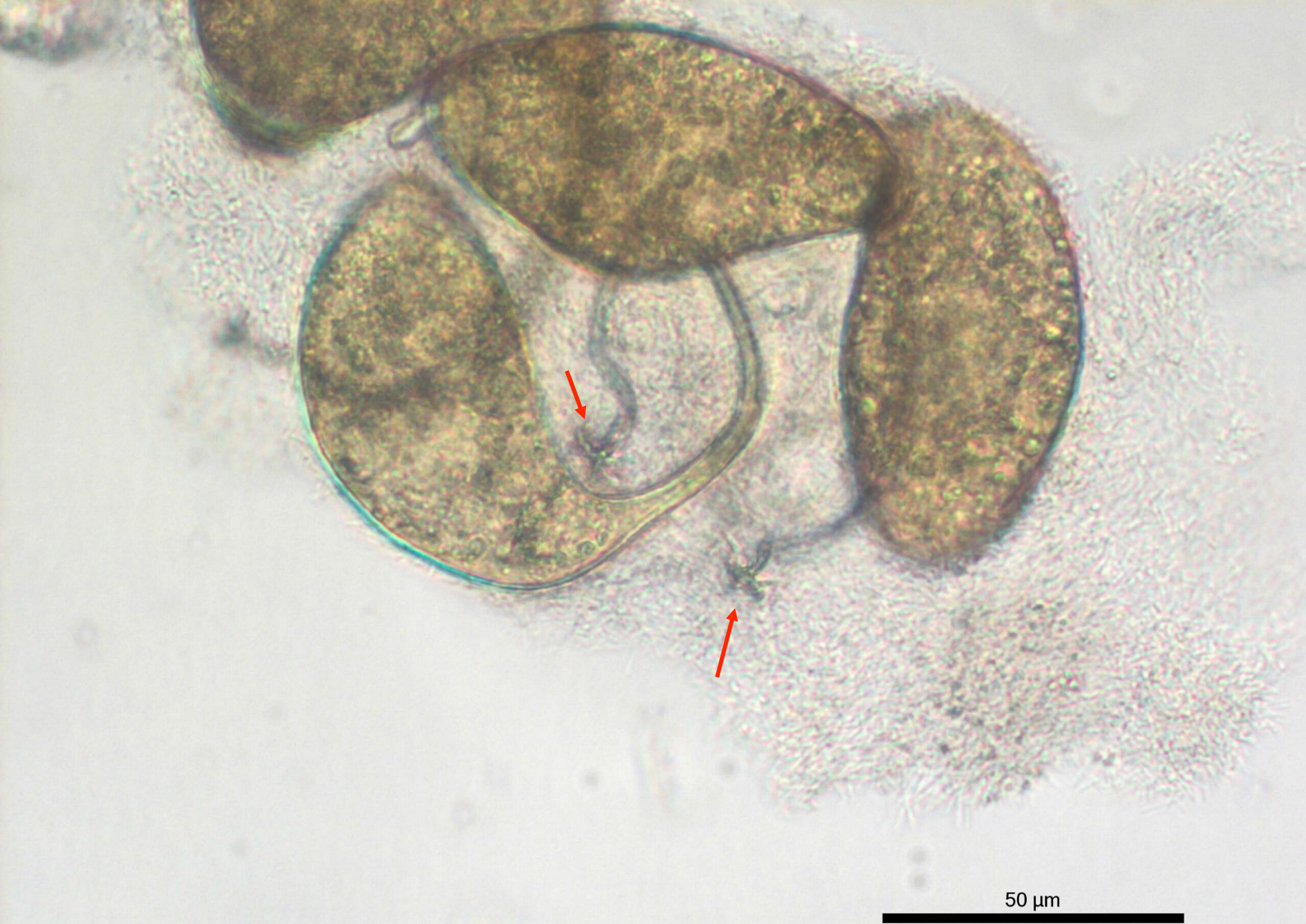- IRTA broodstock in Catalonia Spain
- Recurrent outbreaks of monogeneans
- May 2009, 6 fish
- This year one more
- Samples were sent to HCMR for identification


Karl Andree
Neil Duncan
Ana Roque
Alicia Estevez
Enrique Gisbert

Diplectanum sciaenae



200 μ m





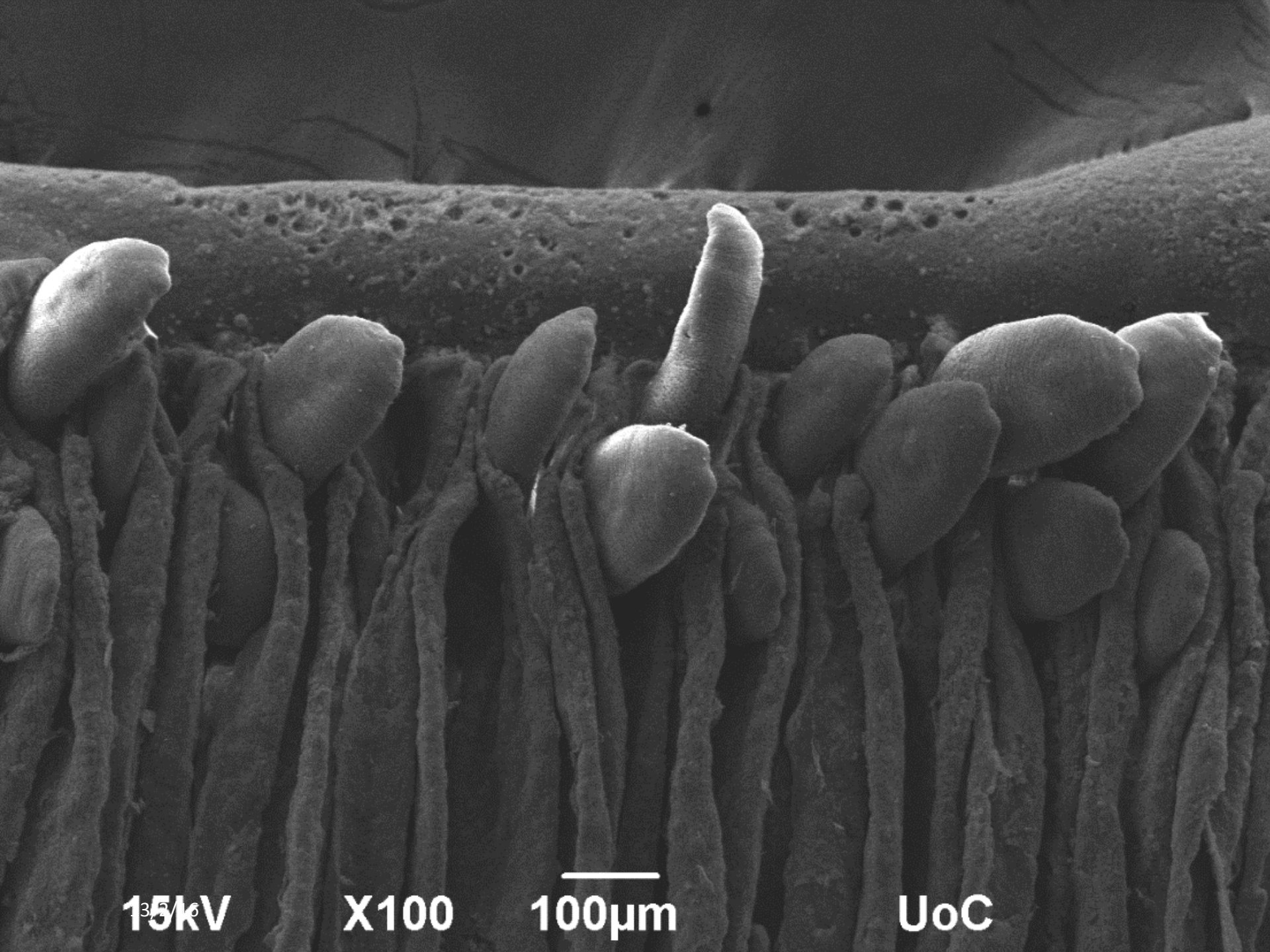
Details of the haptor.
There are 2 squamodisc
one at each side (arrow)

15kV

X500

50µm

UoC



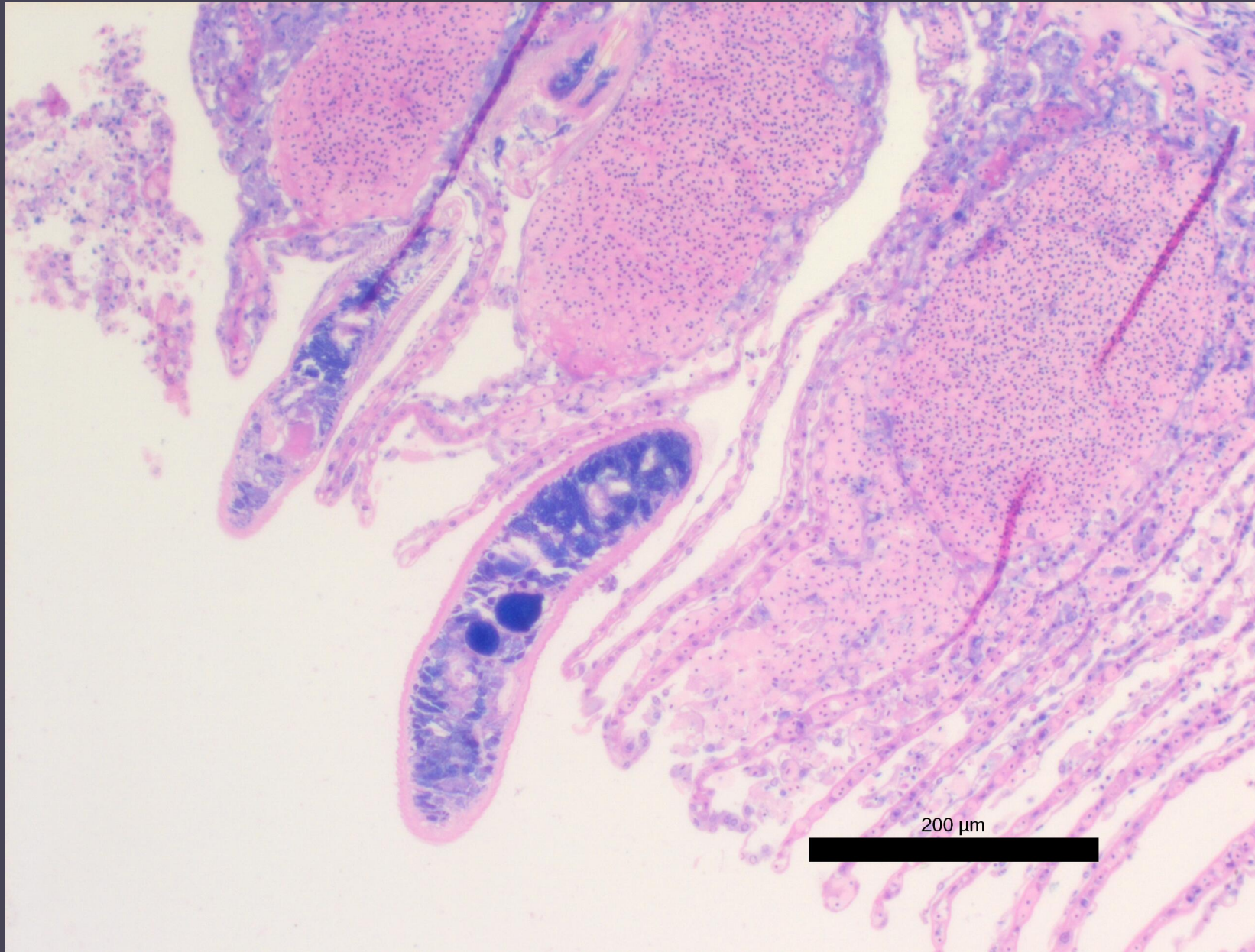
Parasites on the gills

15kV

X100

100µm

UoC




Diplectanum sciaenae (Van Beneden & Hesse, 1863) (Monogenea) infecting meagre, *Argyrosomus regius* (Asso, 1801) broodstock in Catalonia, Spain. A case report.

K. B. Andree¹, A. Roque¹, N. Duncan¹, E. Gisbert¹, A. Estevez¹, M. I. Tsertou², P. Katharios^{2,*}

IRTA, C/ al Poble Nou, Km 5,5 43540 Sant Carles de la Ràpita, Tarragona, Spain

Institute of Marine Biology, Biotechnology and Aquaculture, HCMR, Former American Base of Gournes, Heraklion 71003, Crete, Greece



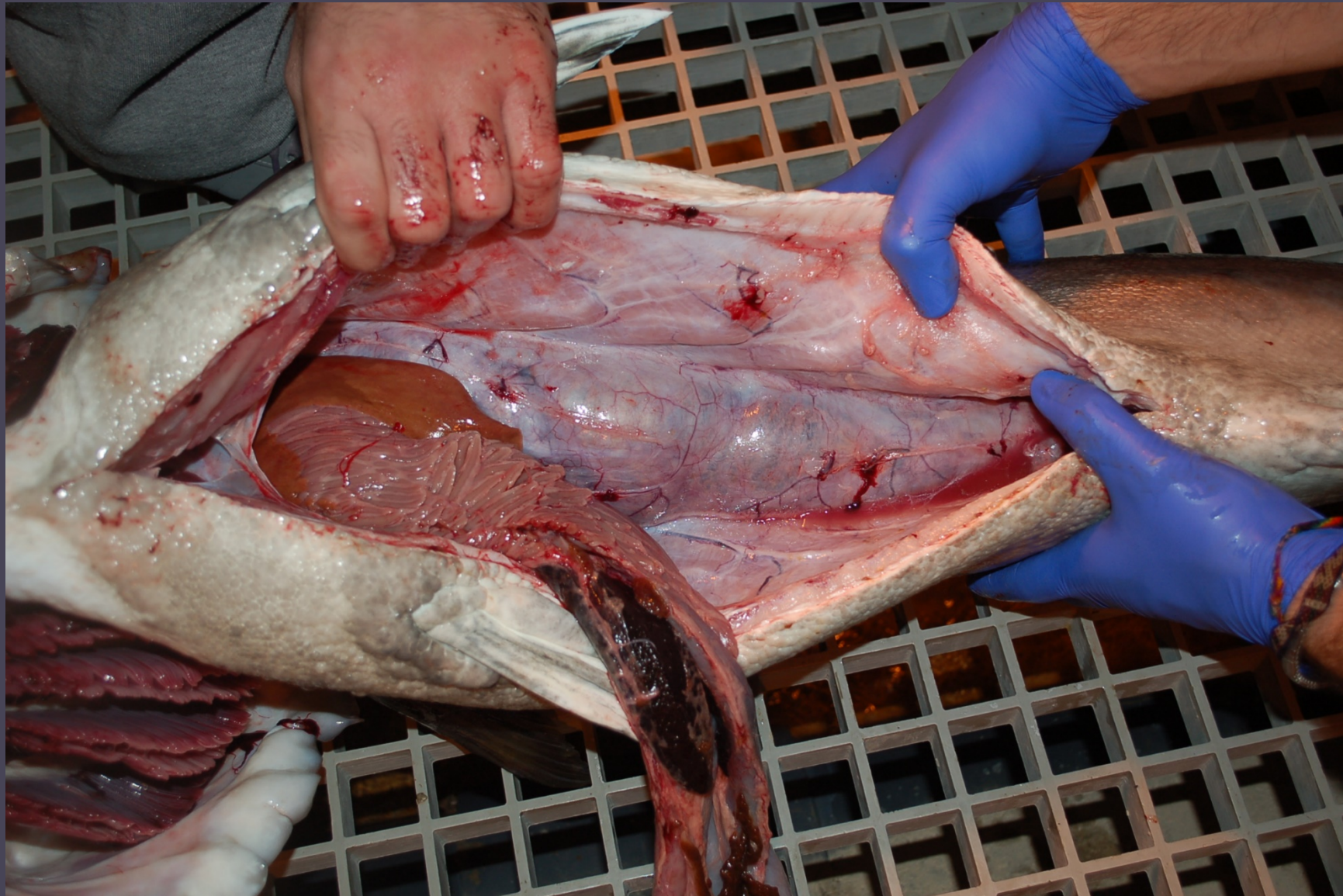Greater amberjack case report

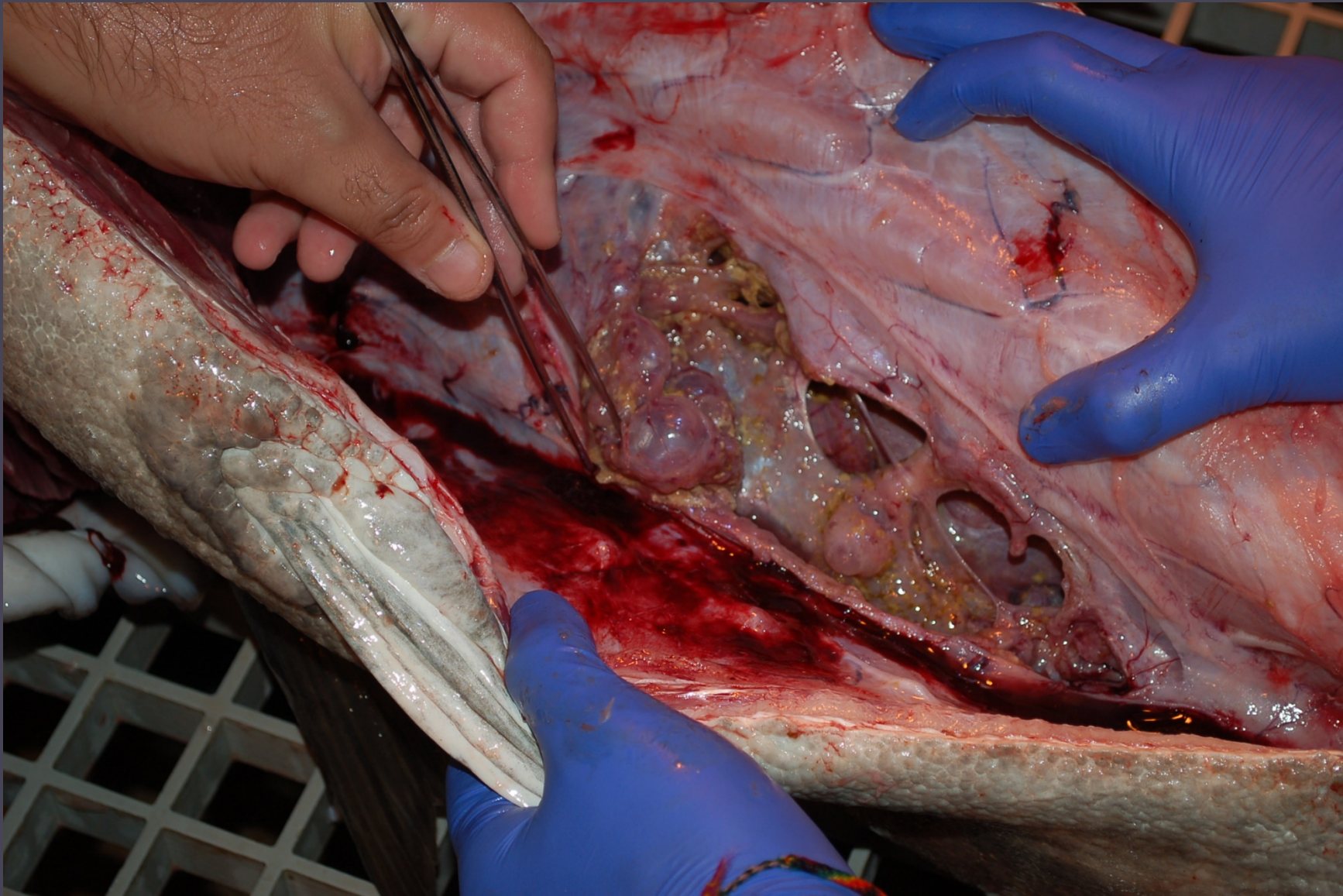
Greater amberjack broodfish

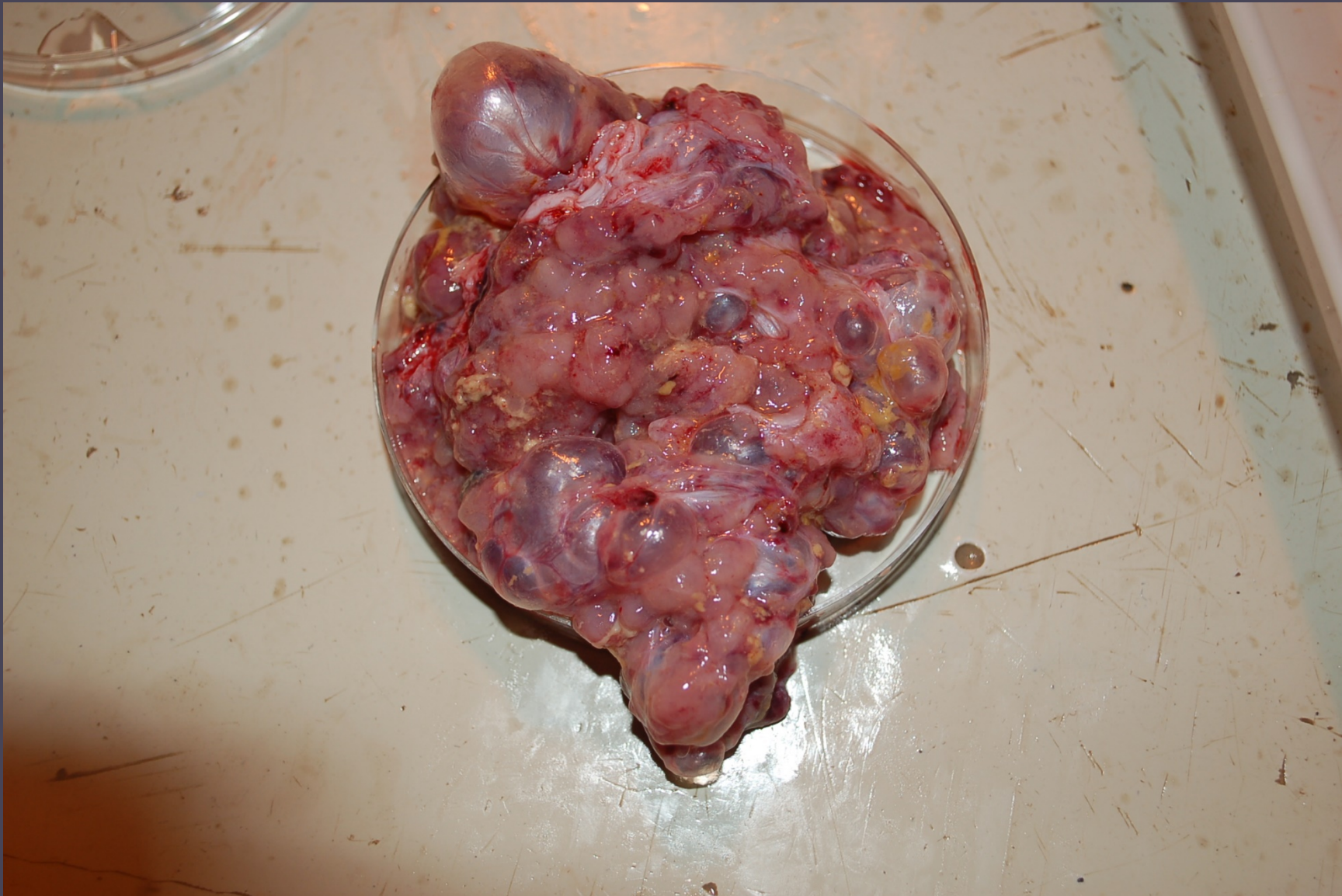- HCMR, Heraklion, Crete
- ~25 kg
- “Spinal” deformity
- Deformed after summer

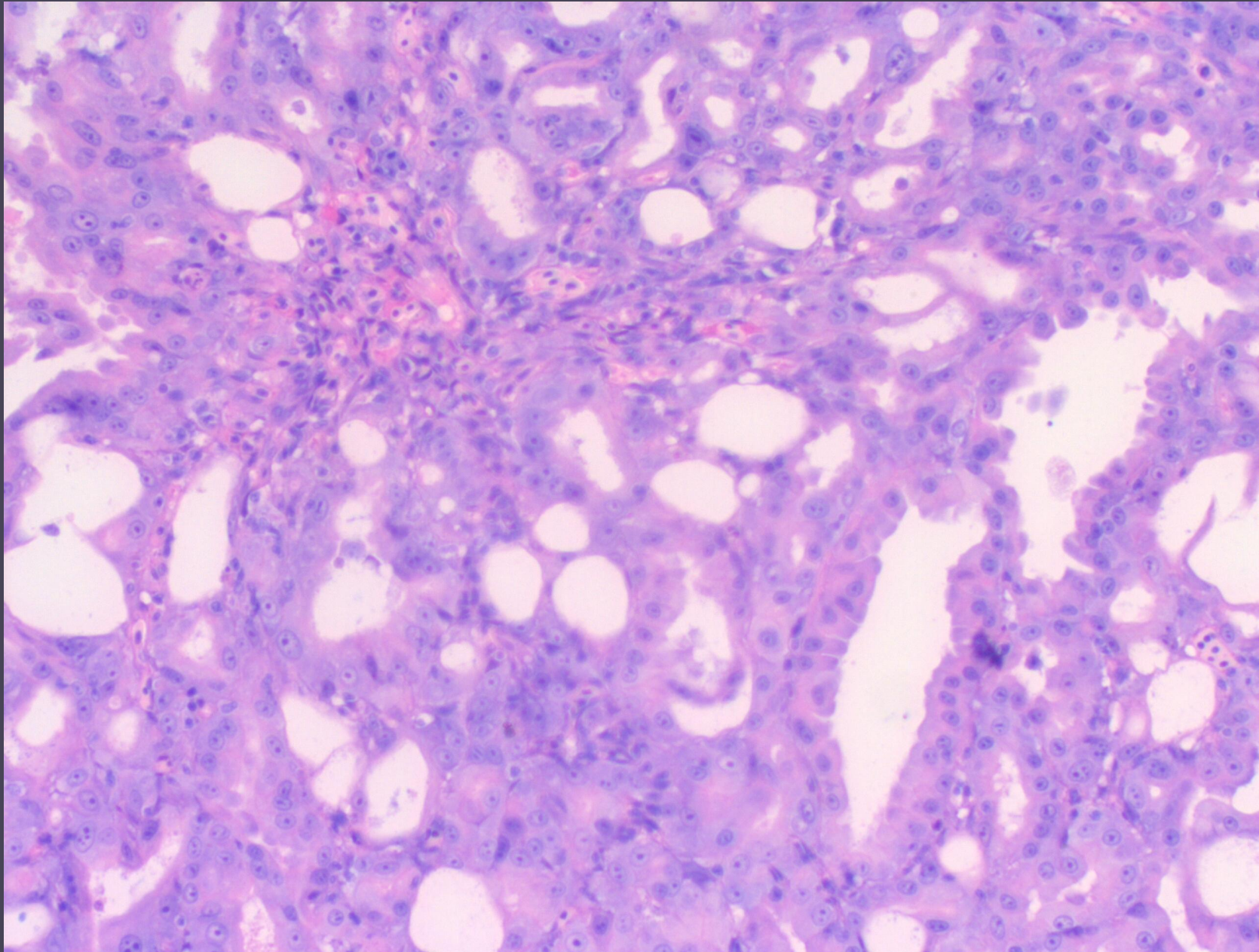


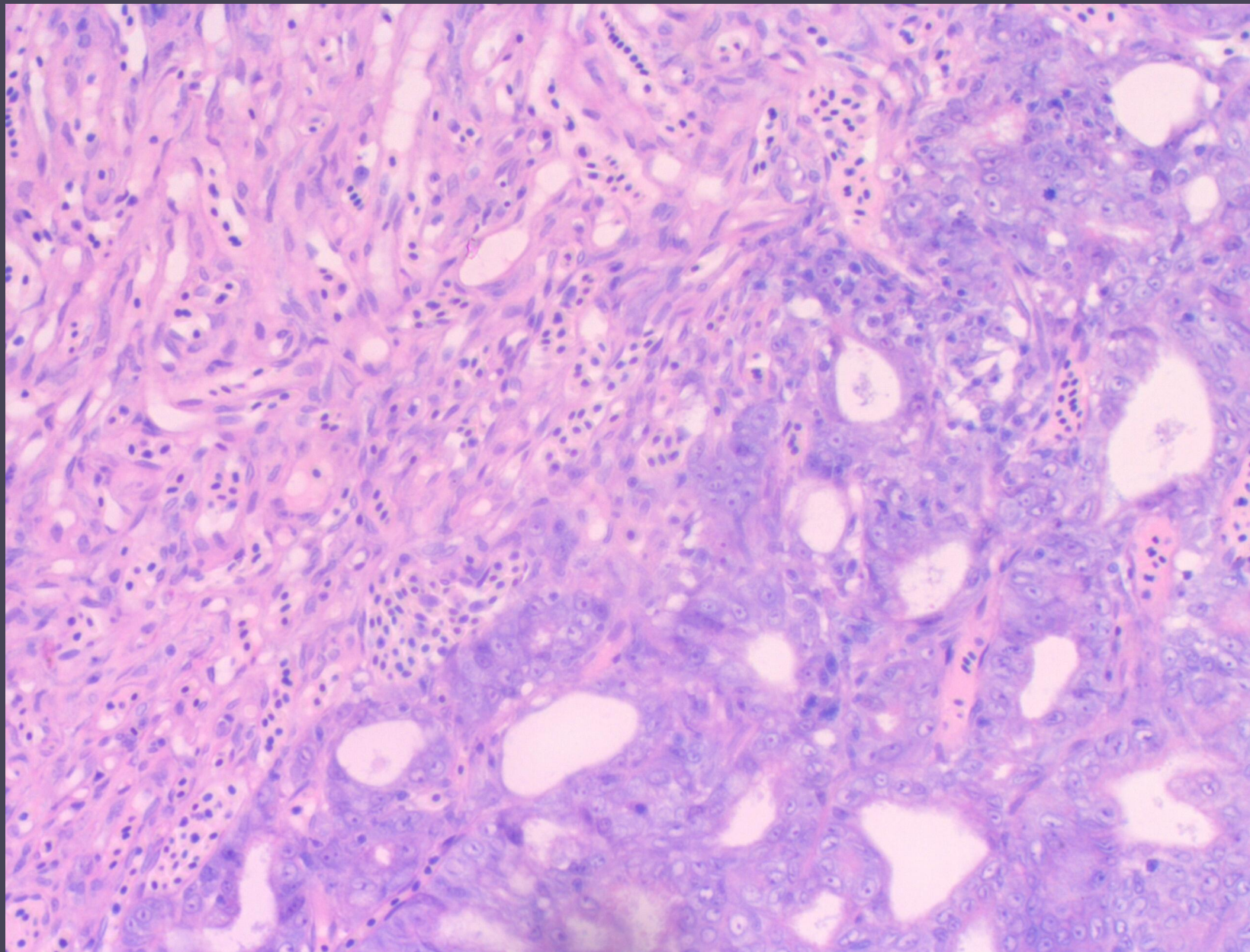










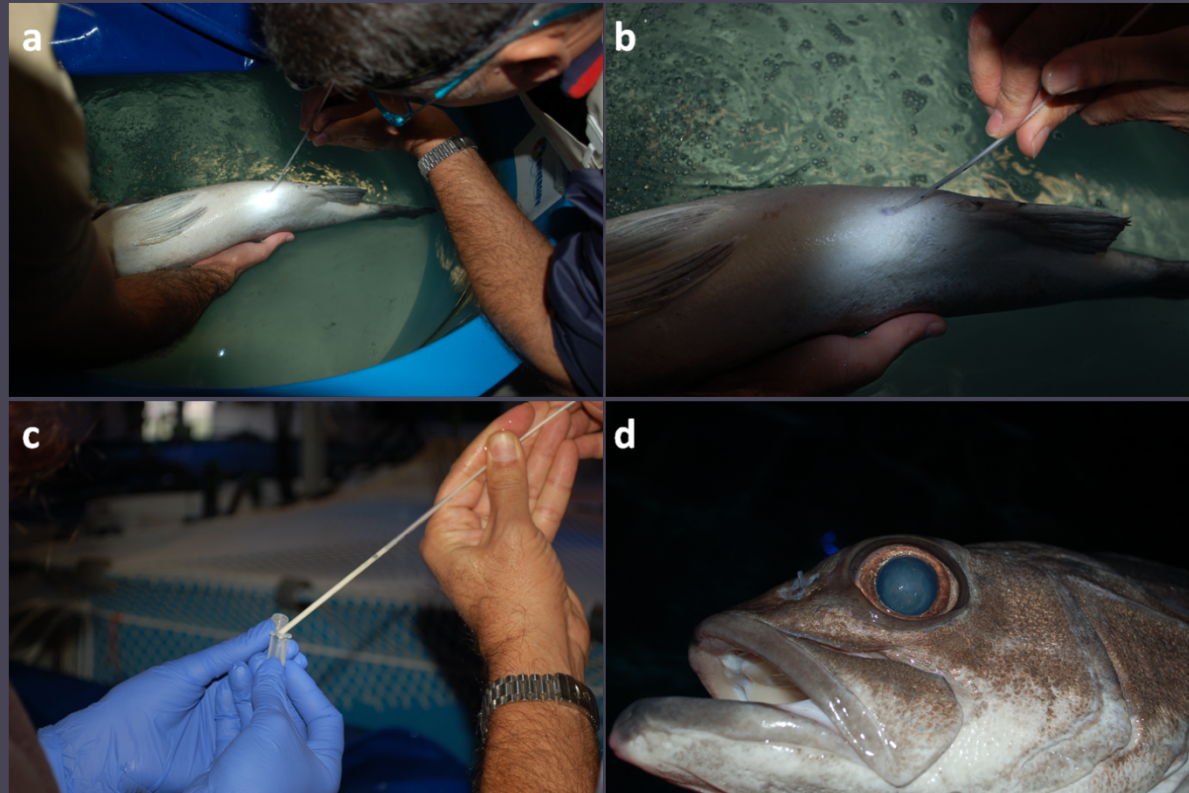


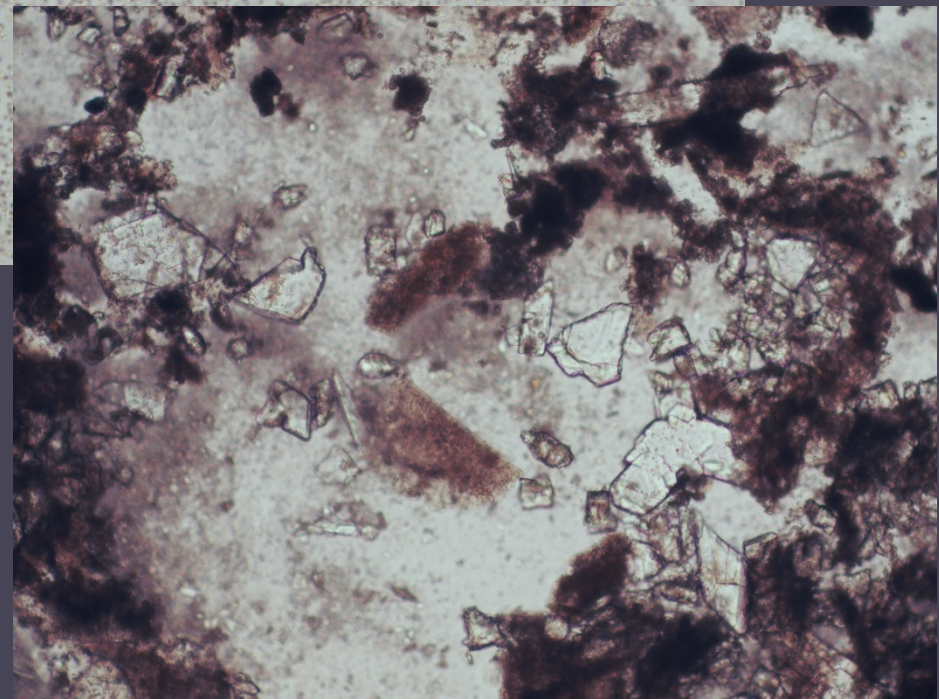

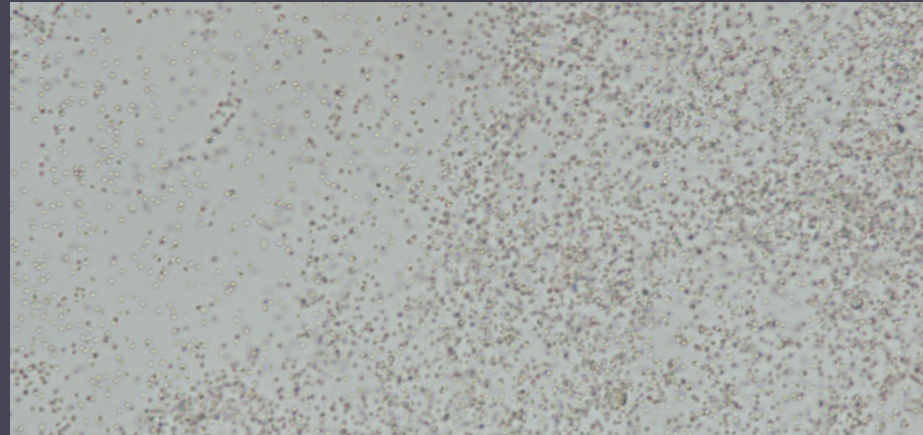

Initial diagnosis

- Adenoid cystic carcinoma
- Samples sent to University of Zurich for verification
- Rare type of cancer in humans
- Never reported in fish

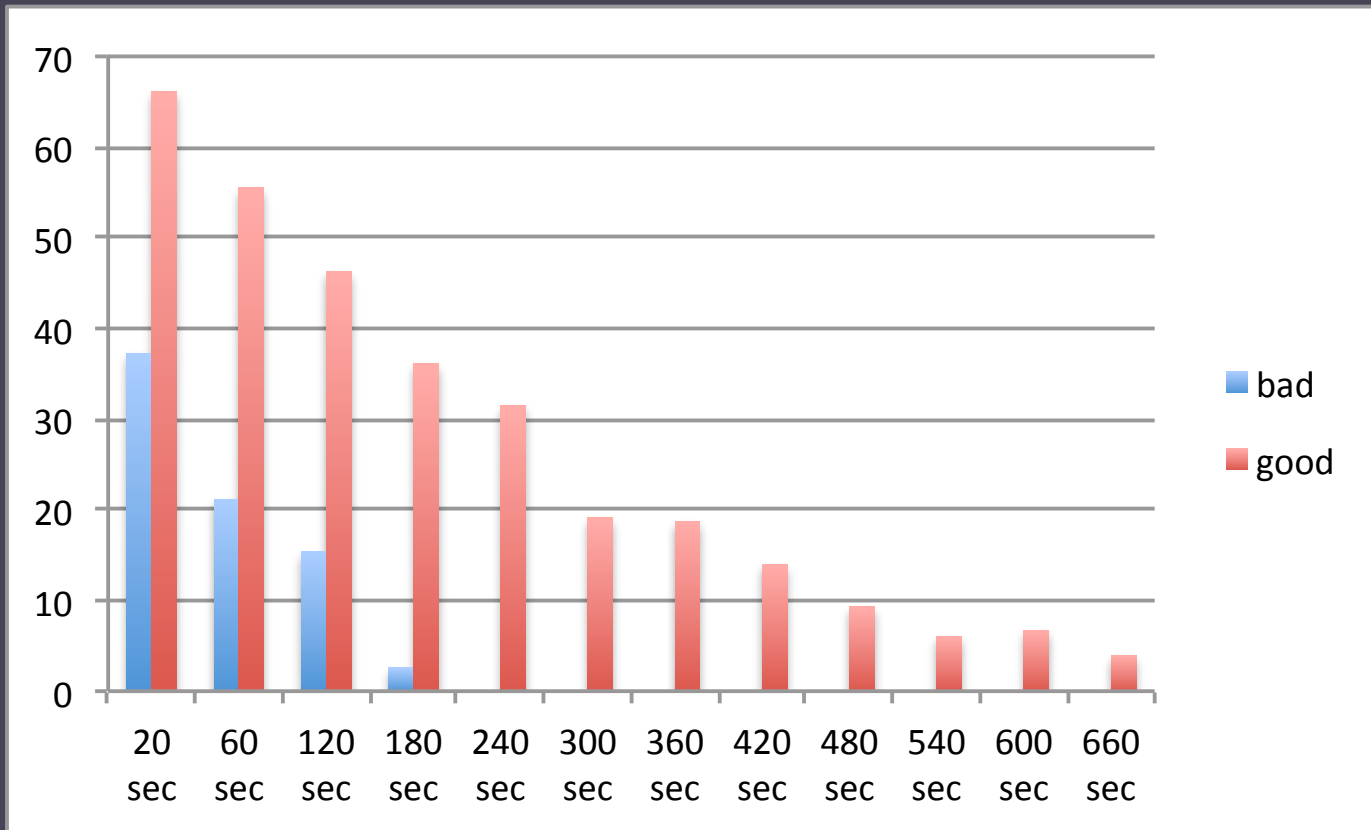
Wreckfish case report

- HCMR. Aqualabs, Heraklion, Crete
- Broodfish ~ 6.5 kg
- Sperm quality issues

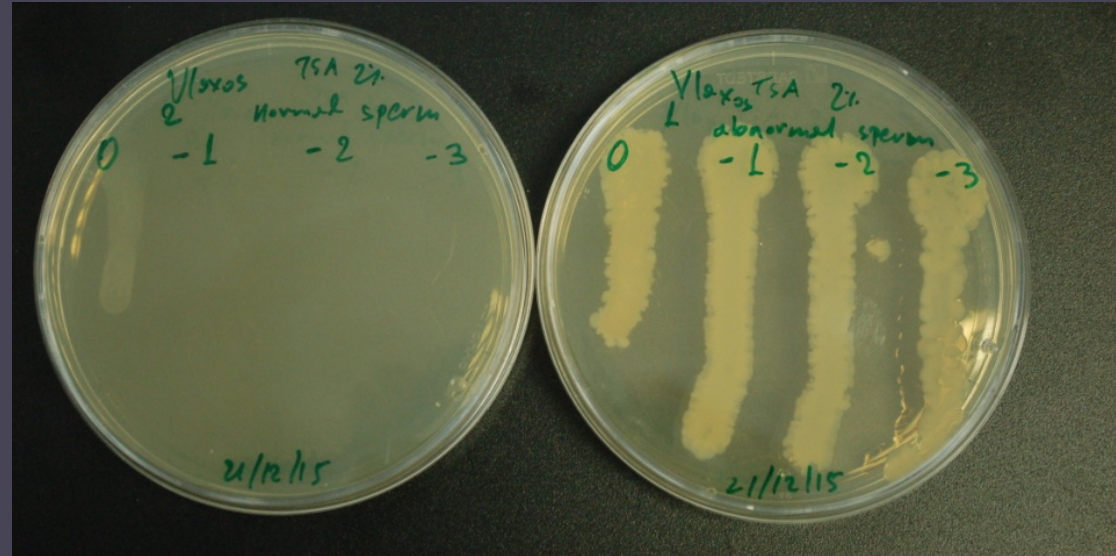




Sperm quality



Ioannis Fakriadis ©



3 different colonies recovered
Total bacteria: 10^8 cfu mL⁻¹
No ID with BIOLOG GENIII
DNA extraction and PCR 16s
Analysis under way

Wreckfish bacterial orchitis

- Antibiotic injection (Enrofloxacin 20 mg kg⁻¹)
- Sampling 2 weeks later
- One type of bacteria (instead of 3) in much lower titer
- Sperm quality still an issue
- Re-injected with antibiotics